

SUPPLEMENTARY MATERIALS

Table S1. Needle electromyography study

	Insertional activity	Spontaneous activity	Motor unit action potentials			IP	
			Normal	Polyphasia	Amplitude		Duration
Lt. brachioradialis	Normal	-	Normal	-	-	-	Full
Lt. pronator teres	Normal	-	Normal	-	-	-	Full
Lt. EDC	Normal	-	Normal	-	-	-	Full
Lt. FDI	Normal	-	Normal	-	-	-	Full
Lt. APB	Normal	-	-	-	Large (8 mV)	Long	Reduced

IP, interference pattern; EDC, extensor digitorum communis; FDI, first dorsal interosseus; APB, abductor pollicis brevis.

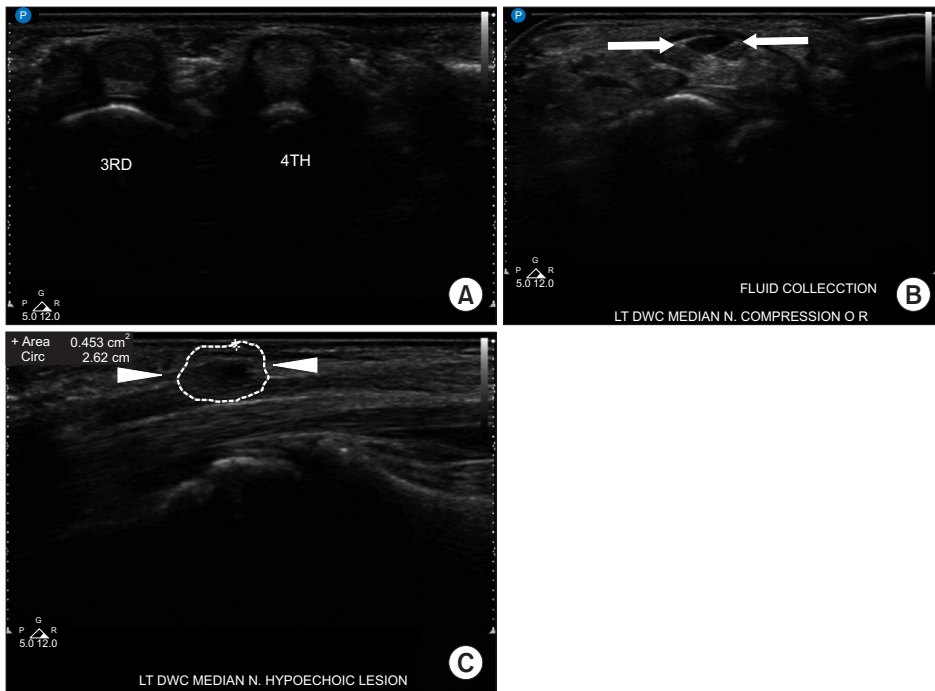


Fig. S1. Transverse ultrasonogram demonstrated no abnormal finding in the palm of left hand including a 3rd web space (A) and compression and swelling of median nerve with fluid collection at distal wrist crease (B and C). Arrows indicate fluid collection, and arrowheads indicate median nerve.